

[www.lifecell.in](http://www.lifecell.in)

LifeCell<sup>®</sup>  
Diagnostics  
is now ▶

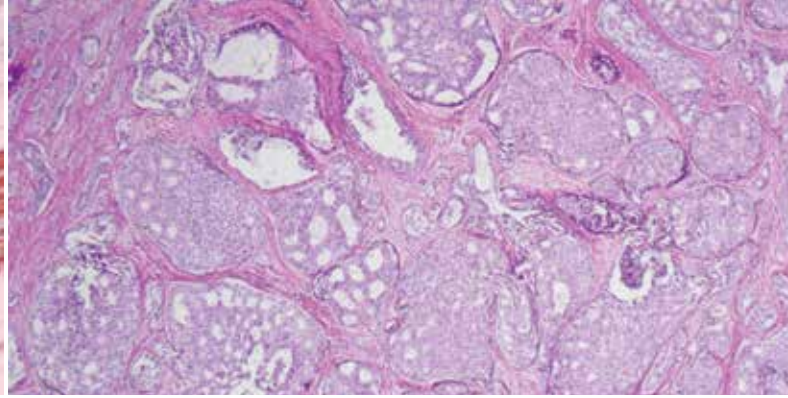
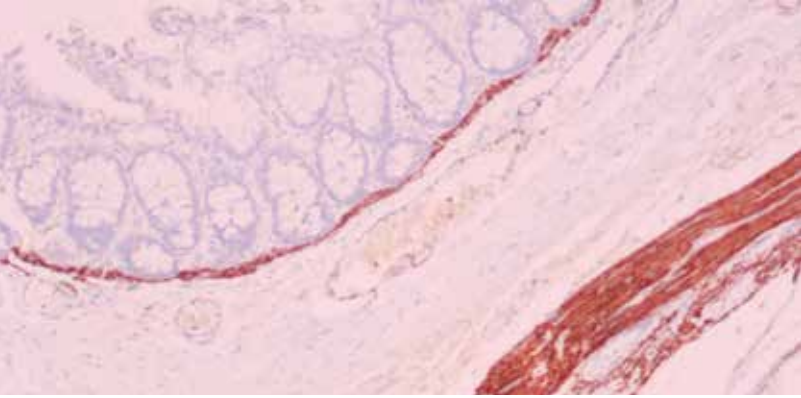
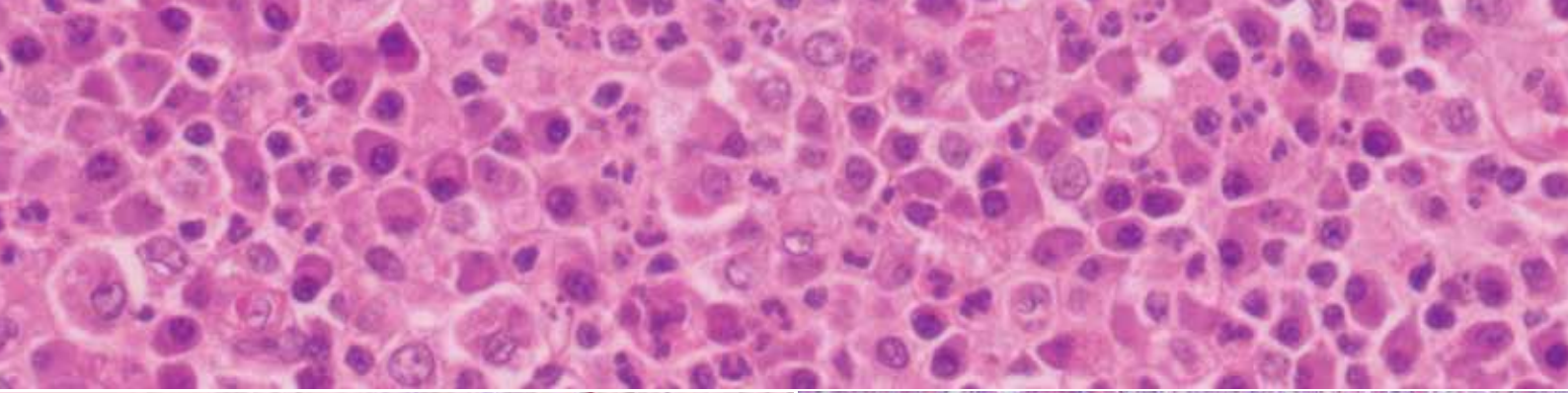
**mfine**  
/diagnostics

# CANCER

nowhere to hide...

Precise  
**Cancer  
Diagnosis**  
with Targeted IHCs

---



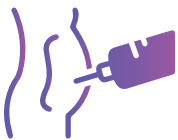
---

# Histopathology@ Lifecell



## BIOPSIES

- Reporting of biopsies, Bonemarrow biopsy and aspiration smear study
- Reporting based on CAP guidelines.
- Renal Pathology including Transplant Pathology
- Direct and Paraffin immunofluorescence based test- Renal and Skin biopsies.



## CYTOLOGY

- FNAC of benign/malignant swelling, USG/CT guided lesions and swelling.
- Fluid analysis for malignant cytology (CSF, Pleural fluid, Peritoneal fluid, Ascitic fluid, Urine, Sputum)
- Cell block and Immunocytochemistry
- Shortest TAT for all cytology specimens



## EXTENSIVE UNPARALLEL SUPPORT

Our Clinical Geneticists, Genetic Counsellors, MD/PhD scientists, clinical and molecular genomics specialists enable us to provide clear, accurate, and meaningful test reports. Their deep knowledge helps in assisting you with any questions that you may have at various stages of the genetic testing process.



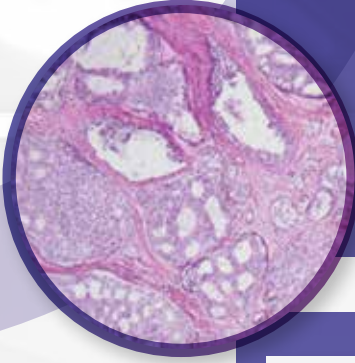
## EXPRESS GENETIC COUNSELLING SERVICES

We offer pre and post test genetic counselling with Board Certified Genetic Counsellor at no additional charge for patients when testing is ordered through LifeCell.

---







# Diagnose precisely by IHC markers upto Final Diagnosis

## Indication



Useful for detection of Haematolymphoid neoplasms (Lymphoma/Leukemia), Soft tissue tumors including spindle cell and round cell tumors, Carcinoma of unknown origin and detection of solid tissue tumors.









## Clinical Utility

-  Biopsy reviewed by Path experts and Unlimited IHC antibodies usage to arrive at the conclusive diagnosis
-  Digital images of positive and specific negative markers
-  The number of markers vary from time to time to arrive at a final diagnosis.
-  Clinician connected for sharing his opinion in the case whenever needed
-  TAT -7 working days
-  Prognostic/ therapeutic markers such as PDL-1, Ros-1, ALK (D5f3), Estrogen receptor, Progesterone receptor and Her2 neu will not be covered in this panel

## Reflex Panels of Prognostic Markers

can be added later like

ER PR Her2 neu ki67, PD-L1, Microsatellite instability tests, etc

-  GIST Panel by IHC
-  Lung panel by IHC
-  Melanoma panel by IHC
-  Anaplastic Lymphoma Kinase (D5F3) by IHC
-  ROS-1 by IHC
-  Breast Cancer Quad panel (ER,PR, Her2neu, Ki-67)
-  PD-L1 (SP263, SP142, 22C3Dako)
-  Microsatellite Instability Panel for Colorectal Carcinoma by IHC (MSH2, MSH6, MLH1 and PMS2)

# Report Illustration

Name:	Mrs. Dummy	CRM:	222XXXXX1233X	Collected:	xx-xx-xxx	Status:	Final
Age:	XX Years	Location:	DEMO	Received:	xx-xx-xxx 12:57	Sample Quality:	Adequate
Gender:	Female	Lab ID:	20xxxxxxx2	Reported:	xx-xx-xxx 14:43	Client:	Demo Center

## FINAL DIAGNOSIS PANEL REPORT - IHC

### SPECIMEN:

Specimen of DEMO

### SPECIMEN NO:

HP22-XX.

### CLINICAL SIGNIFICANCE:

Thoracic mass biopsy in a 9 year Male child. DD: Rhabdomyosarcoma, Germ cell tumor, Lymphoblastic leukemia

### GROSS

Received one block for review labeled 'xxy', a thoracic mass biopsy in a xx year male child.

### MICROSCOPY DESCRIPTION:

The tumor cells are immunopositive for SALL4 (Diffuse nuclear positive) , CD117 (Diffuse membranous positive) and Cytokeratin (focal dot like positivity) while they are immunonegative for Myogenin and CD45. The lymphocytes are highlighted by CD45. Overall features are that of an extragonadal germ cell tumor consistent with Seminoma.

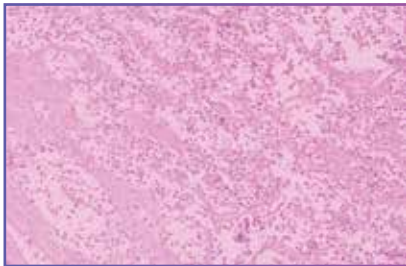
### IMPRESSION:

Seminoma, Thoracic mass biopsy.

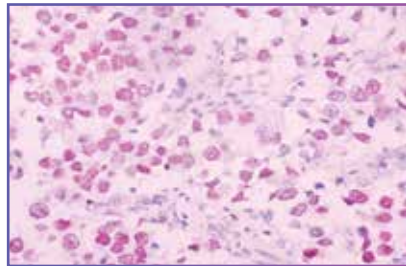
### SUMMARY:

SALL4- Diffuse nuclear positive  
CD117- Diffuse membranous positive  
Cytokeratin- Focal cytoplasmic positive  
Myogenin- negative  
CD45- negative in tumor cells, Positive in lymphocytes  
Controls are adequate and satisfactory.

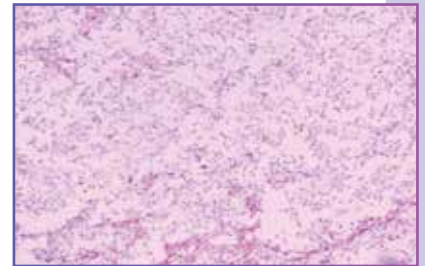
**Reference:** WHO Classification of Tumors of the Lung, Pleura, Thymus and Heart, 4th edition.



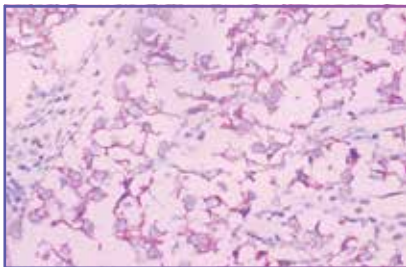
H&E stain, 10x



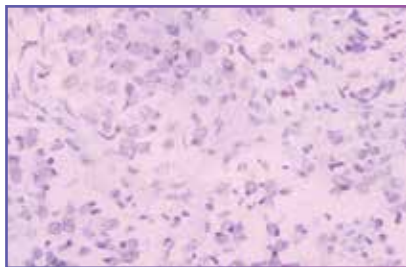
SALL4, 40x



CD45,10x, positive in lymphocytes



CD117, 40x



Cytokeratin, 40x



Myogenin,10x

Name of Salesperson: ..... Contact: .....